

A 43-Year-Old Male with *PCM1-JAK2* Gene Fusion Experienced T-Lymphoblastic Lymphoma, Myelofibrosis, and Acute Myeloid Leukemia

Tsai CC¹, Su YCMD¹, Chen BJ², Hsieh SM³, Whang-Peng J⁴, Chao TY^{*1,5}

¹Division of Hematology and Oncology, Department of Internal medicine, Taipei Medical University-Shuang Ho Hospital, New Taipei City, Taiwan, (R.O.C.)

²Department of Pathology, Taipei Medical University-Shuang Ho Hospital, New Taipei City, Taiwan, (R.O.C.)

³Department of Clinical Pathology, Taipei Medical University-Shuang Ho Hospital, Taiwan, (R.O.C.)

⁴Cancer Center, Wan Fang Hospital, Taipei Medical University, Taipei, Taiwan, (R.O.C.)

⁵International Ph.D. Program in Medicine, College of Medicine, Taipei Medical University, Taipei City, Taiwan, (R.O.C.)

Volume 2 Issue 3- 2020

Received Date: 25 Jan 2020

Accepted Date: 08 Feb 2020

Published Date: 12 Feb 2020

2. Keywords

PCM1-JAK2, T-lymphoblastic lymphoma, myelofibrosis, acute myeloid leukemia

1. Abstract

Myeloid/lymphoid neoplasms associated with eosinophilia and *PCM1-JAK2* is a provisional entity in WHO 2016. Prior case reports have shown quite a few clinical presentations in different patients with this chromosome translocation, characterized by eosinophilia in combination with myelodysplastic/myeloproliferative neoplasms, acute myeloid leukemia (AML) and rarely, T-lymphoblastic lymphoma (T-LBL) or B-acute lymphoblastic leukemia (B-ALL). We herein reported a case who initially was diagnosed as T-LBL with myelofibrosis. He developed AML after chemotherapy for T-LBL. We used fluorescence in situ hybridization (FISH) analysis proves the presence of *PCM1-JAK2* fusion in his tumor cells. Our case with the unique feature of AML transformation from initial T-LBL provides a further evidence in support of the provisional entity of myeloid/lymphoid neoplasm with *PCM1-JAK2*.

3. Introduction

Molecular genetic abnormalities, such as PDGFRA, PDGFRB, FGFR1, in myeloid/lymphoid neoplasms associated with eosinophilia is one of the category of myeloid neoplasms in WHO classification 2008. In 2016, the WHO introduced a new provisional entity *PCM1-JAK2* into this category [1]. The first description of a patient with t(8;9)(p22;p24) was reported by Stewart et al in 1990 [2]. Reiter et al used reverse transcription-PCR and FISH to identify the recurrent *PCM1-JAK2* fusion gene in patients with t(8;9)(p21-23;p23-24) in 2005 [3]. Since then there have been at least 33 patients reported with a lymphoid or myeloid neoplasm associated with t(8;9)(p22;p24);*PCM1-JAK2* [4, 5]. These patients' characteristics are very similar to those with rearrangements of PDGFRA, PDGFRB, or FGFR1 with regard to epidemiology, clinical features, and genetic changes [5]. This disease entity is rare and characterized by a combination of eosinophilia with the

bone marrow findings of left-shifted erythroid predominance, lymphoid aggregates, and often myelofibrosis, at times mimicking primary myelofibrosis. Even rarer, it can present as T- or B-acute lymphoblastic leukemia (ALL) [4]. There is a marked male predominance with a gender ratio of 27:5. The age range is wide, from 12 to 75 years old with a median of 47. Clinical features often include hepatosplenomegaly [3, 4]. We report herein a 43-year-old man, who has t(8;9)(p22;p24);*PCM1-JAK2*, experienced T-lymphoblastic lymphoma (T-LBL), gradually progressive to myelofibrosis after initial treatment and finally developed blastic transformation into acute myeloid leukemia (AML).

4. Material and Methods

4.1. Case Report

A 43-year-old Taiwanese man sought for medical attention due to multiple enlarged clustered lymph nodes in bilateral

*Corresponding Author (s): Tsu Yi Chao MD, Division of Hematology and Oncology, Department of Internal medicine, Taipei Medical University-Shuang Ho Hospital, New Taipei City, 23561, Taiwan, (R.O.C.), E-mail: 10575@s.tmu.edu.tw

Citation: Chao TY, A 43-Year-Old Male with *PCM1-JAK2* Gene Fusion Experienced T-Lymphoblastic Lymphoma, Myelofibrosis, and Acute Myeloid Leukemia. Clinics of Oncology. 2020; 2(3): 1-4

neck, hepatomegaly and abnormal laboratory data including leukocytosis, anemia, thrombocytopenia and leukoerythroblastosis in December, 2017. A neck lymph node biopsy showed T-LBL (Figure 1). A bone marrow biopsy revealed myeloproliferative neoplasm (MPN)-like morphology with hypercellularity, increase in eosinophils, and myelofibrosis grade 1 (0-3) by reticulin stain

without increase in blasts or involvement of T-LBL (Figure 1). He then received treatment with a regimen from Taiwan Pediatric Oncology Group 2013 for high risk-ALL protocol, in which including an induction, a consolidation and a continuation phase. However, after the 8th week treatment of continuation phase, a CBC showed a WBC count of $157.90 \times 10^9/L$, a hemoglobin of 6.9 g/dL,

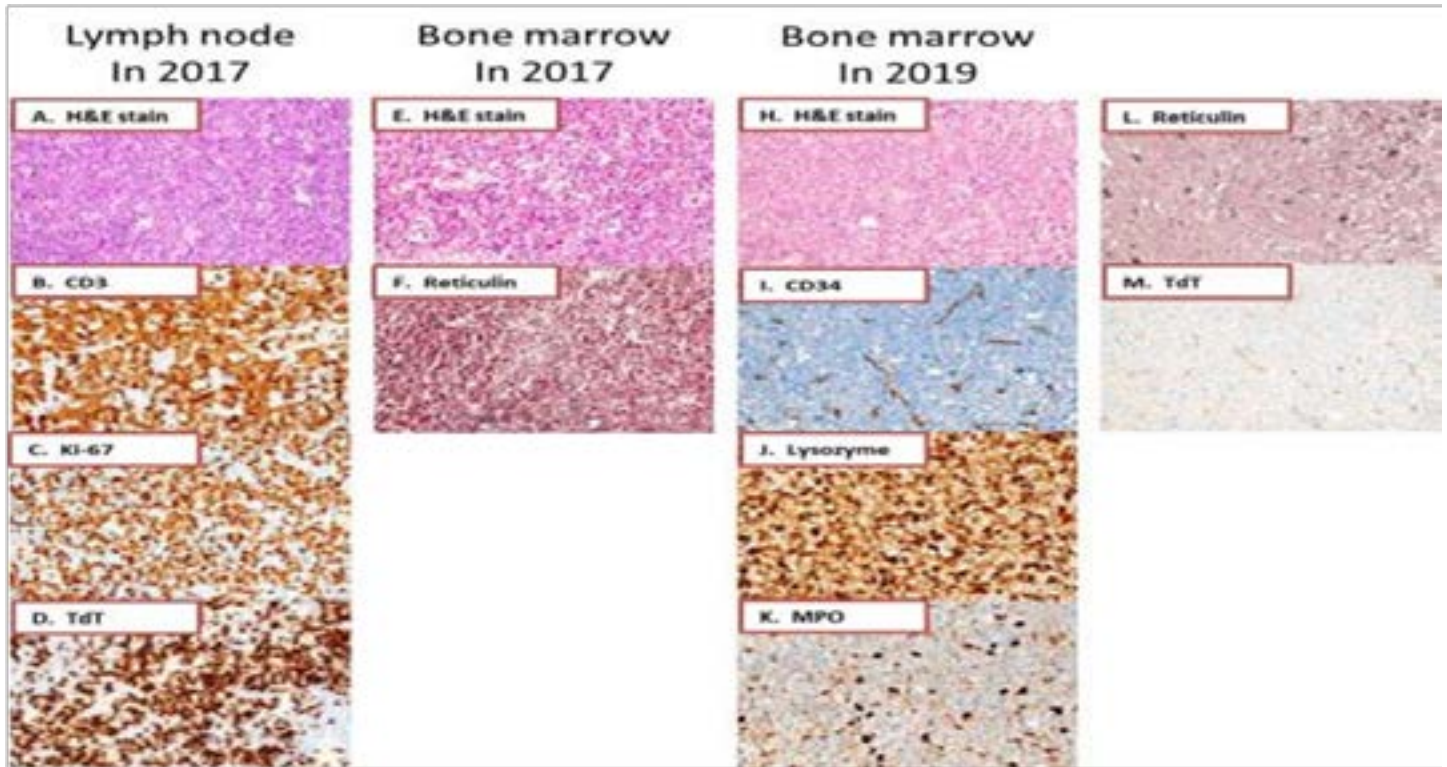


Figure 1: The initial lymph node biopsy in 2017 showed T-lymphoblastic lymphoma composed of medium-sized lymphoblasts with fine chromatin and round to irregular convoluted nucleus (A). Immunohistochemically, these lymphoblasts express CD3 (B), TdT (D), and CD1a with high Ki-67 proliferation index (C), compatible with T-lymphoblastic lymphoma; the initial bone marrow biopsy in 2017 showed myeloproliferative neoplasm-like morphology with hypercellularity, increase in eosinophils (E), and grade 1 fibrosis (0-3) by reticulin stain (F). Neither increase in blasts nor involvement of T-lymphoblastic lymphoma was seen; the follow-up bone marrow biopsy in 2019 showed blast transformation into acute myeloid leukemia with sheets of blasts (H). These blasts are positive for lysozyme (J), CD4, and CD68R (partial), but negative for CD3, CD34 (I), CD117, myeloperoxidase (K), and TdT (M), compatible with acute myeloid leukemia with monocytic differentiation. Reticulin stain (L) displays grade 2 fibrosis (0-3). (all panels with x400 magnification)

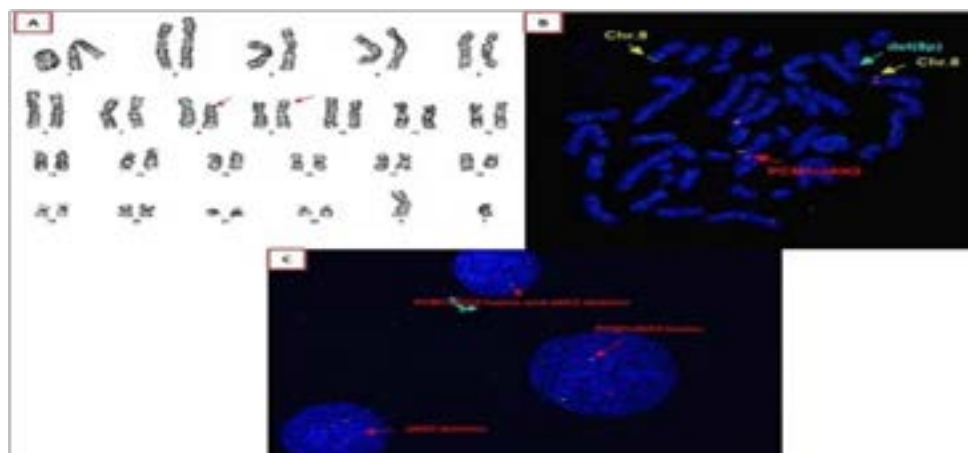


Figure 2: Cytogenetics of bone marrow aspirates in 2017 & 2019 both showed $t(8;9)(p22;p24)$ (A). Fluorescence in situ hybridization (FISH) analysis using PCM1-JAK2 dual-fusion probe proves PCM1-JAK2 fusion in metaphase (B, x1000) and interface (C, x1000). (green signal: JAK2 gene in chromosome 9; orange signal: PCM1 gene in chromosome 8; yellow signal: PCM1-JAK2 fusion)

a platelet of 38×10^9 /L, leukoblastosis (band 9%, metamyelocyte 5%, myelocyte 13%, promyelocyte 24%) and blast cells around 10%. A bone marrow biopsy displayed blastic transformation into AML, accompanied by increase in eosinophils and myelofibrosis grade 2 (0-3) by reticulin and Masson-Trichrome stains (Figure 1). In consideration of the previous T-LBL and MPN-like morphology with increased eosinophils and further blastic transformation in the bone marrow, myeloid/lymphoid neoplasm with eosinophilia and gene rearrangement was considered. Cytogenetic study of the bone marrow aspirates showed 46,XY,t(8;9)(p22;p24), and fluorescence in situ hybridization (FISH) analysis showed PCM1-JAK2 fusion (Figure 2). Other recurrent genetic abnormalities of AML were negative, including AML1-ETO(RUNX1-RUNX1T1), CBFβ-MYH11 and MLL-PTD fusion transcripts; NPM1, FLT3-ITD and FLT3-TKD mutations. The patient then received induction and consolidation treatment with I3A7 and HiDAC while the manuscript was being prepared.

5. Discussion

Myeloid/lymphoid neoplasms with eosinophilia and PCM1-JAK2 is a new provisional entity in WHO 2016 classification of myeloid neoplasms. Prior case reports have shown quite a few clinical presentations in different patients with this chromosome translocation, characterized by eosinophilia in combination with myeloproliferative neoplasms, myelodysplastic/myeloproliferative neoplasms, AML and rarely, T-LBL or B-ALL. The present case initially presented as T-LBL, and finally became an AML, with progressive bone marrow fibrosis. The presentation is unique in this category.

JAK2 is a non-receptor tyrosine kinase essential for such hormone-like cytokines as growth hormone (GH), prolactin (PRL), erythropoietin (EPO), thrombopoietin (TPO) and the family of cytokines that signal through the IL-3 receptor. JAK2 point mutation, such as V617F, accounts for some MPN [6]. The protein PCM1-1 localizes to cytoplasmic granules known as “centriolar satellites” which is involved in microtubule organization in interphase [7]. Although the functions of each gene have been discovered partially, what effects of this fusion gene for leukaemogenesis is still unclear.

In recent years, many gene mutations and chromosome abnormalities have been discovered with correlation to leukaemogenesis via multiple steps toward the development of AML. The gene mutations or chromosome abnormalities act together to induce progression from normal haematopoietic stem/progenitor cells to clonal, preleukemic stem/progenitor cells, to overtly transformed leukaemic cells [8].

In T-LBL, the leukemogenic events are mostly caused by translocation placing the proto-oncogene under control of a T cell receptor (TCR) promoter or enhancer, or transcription factor juxtaposition to TCR loci. Oncogenic fusion proteins are less common in the leukaemogenesis but indeed present. ETV6-JAK2 is one of them, and is found in B- and T-LBL [1, 9]. Perhaps, PCM1-JAK2 could also form the fusion protein leading to the leukemogenic event.

Although why the fusion gene PCM1-JAK2 develops a broad spectrum of clinical presentation is not clear, yet the fact that the blast crisis can be myeloid or lymphoid implies that this disease might derive from a pluripotent stem cell [10, 11]. The interaction between the each function of PCM1 and JAK2 within a fusion gene should be clarified in the future. Based on the emerging findings of genetic mutations which contribute to the multiple steps toward the development of lymphoid and myeloid leukemia, we propose that other oncogenes may also play a role, e.g. interaction with PCM1-JAK2 fusion protein on the final progression of this neoplasm toward myeloid or lymphoid neoplasms.

In our case, though, the patient developed AML after chemotherapy, it is difficult to distinguish *novo* AML from t-AML. Because t(8;9)(p22;p24) existed from the first diagnosis of T-LBL, it may support the notion that this translocation dictates the final transformation of AML.

In summary, we reported a case with PCM1-JAK2 fusion, who presented initially with T-LBL with progression to myelofibrosis after chemotherapy and finally with blastic transformation to AML. Our case provides a further evidence in support of the provisional entity of myeloid/lymphoid neoplasm with PCM1-JAK2 reported in the 2016 WHO categories of myeloid neoplasms and acute leukemia.

6. Acknowledgements

We thank Yung -Cheng Su for funding this study and the molecular laboratory in Taipei Medical University-Shuang Ho Hospital for performing the fluorescence in situ hybridization.

References

- Arber DA, Orazi A, Hasserjian R, Thiele J, Borowitz MJ, Le Beau MM et al. The 2016 revision to the World Health Organization classification of myeloid neoplasms and acute leukemia. *Blood*. 2016; 127: 2391-405.
- Stewart K, Carstairs KC, Dube ID, Keating A. Neutrophilic myelofibrosis presenting as Philadelphia chromosome negative BCR nonrearranged chronic myeloid leukemia. *American Journal of Hematology*. 1990; 34:

59-63.

3. Reiter A, Walz C, Watmore A, Schoch C, Blau I, Schlegelberger B et al., The t(8;9)(p22;p24) Is a Recurrent Abnormality in Chronic and Acute Leukemia that Fuses PCM1 to JAK2. *Cancer Res.* 2005; 65: 2662-7.

4. Bain BJ, Ahmad S. Should myeloid and lymphoid neoplasms with PCM1-JAK2 and other rearrangements of JAK2 be recognized as specific entities? *Br J Haematol.* 2014; 166: 809-17.

5. Patterer V, Schnittger S, Kern W, Haferlach T, Haferlach C. Hematologic malignancies with PCM1-JAK2 gene fusion share characteristics with myeloid and lymphoid neoplasms with eosinophilia and abnormalities of PDGFRA, PDGFRB, and FGFR1. *Ann Hematol.* 2013; 92: 759-69.

6. Yamaoka K, Saharinen P, Pesu M, Et Holt V, Silvennoinen O, O'Shea JJ. The Janus kinases (Jaks). *Genome Biology.* 2004; 5: 253.

7. Dammermann A, Merdes A. Assembly of centrosomal proteins and microtubule organization depends on PCM-1. *J Cell Biol.* 2002; 159: 255-66.

8. Swerdlow SH, Campo E. WHO classifications of tumours of haematopoietic and lymphoid tissues 2016.

9. Rabin KR, Margolin J, Poplack DG. Molecular Genetics of ALL, in *The Molecular Basis of Cancer*. 4th ed., J. Mendelsohn, et al., Editors. 2014; 361-69.

10. Robyn J, Lemery S, McCoy JP, Kubofcik J, Kim YJ, Pack S et al., Multilineage involvement of the fusion gene in patients with FIP1L1/PDGFR A-positive hypereosinophilic syndrome. *Br J Haematol.* 2006; 132: 286-92.

11. Chaffanet M, Popovici C, Leroux D, Jacrot M, Adelaide J, Dastugue N et al. t(6;8), t(8;9) and t(8;13) translocations associated with stem cell myeloproliferative disorders have close or identical breakpoints in chromosome region 8p11-12. *Oncogene.* 1998; 16: 945-9.